

Conservative Augmentation with Periareolar Mastopexy Reduces Complications and Treats a Variety of Breast Types

A 5-Year Retrospective Review of 100 Consecutive Patients

Clifton L. Cannon III, MD, and John T. Lindsey, MD

Abstract: Augmentation with mastopexy remains a challenge because reported complication and revision rates remain high. Previous publications are difficult to interpret because of inclusion of a broad array of mastopexy techniques and different implant styles and placements. This is a review of 100 consecutive augmentation/mastopexy patients performed by a single surgeon using a single procedure, implant style, and placement.

Between January 2003 and December 2008, 100 female patients underwent primary augmentation mammoplasty with periareolar mastopexy. All patients had either grade II or grade III ptosis, or tubular deformity. All implants were Allergan style 168 (270–390 mL saline prosthesis).

All patients (N = 100) were available for follow-up, an average 8.3 months postoperatively (1.5–21 months). Overall complication rate was 11%. Nonimplant-related complication rate was 6%—2 widened scars, 3 hypertrophic scars, and 1 partial nipple necrosis. Implant-related complication rate was 5%—2 deflations, 1 capsular contracture, 1 implant shifting, and 1 infection.

Augmentation mammoplasty with periareolar mastopexy treats a wide variety of breast types including tubular deformity and grade II and III ptosis. Planned nipple-areolar elevation should be 4 cm or less. Vertical and horizontal skin envelope redraping is tailored for each case.

Key Words: breast augmentation, periareolar mastopexy, mammoplasty, complication rate, tubular deformity, grade II ptosis, saline breast implant

(*Ann Plast Surg* 2010;64: 516–521)

Augmentation with mastopexy continues to be the most frequently litigated operation in plastic surgery, reflecting the high complication rates and poor outcomes associated with these combined procedures.^{1,2} However, breast ptosis and tubular deformity are common findings among patients seeking breast enlargement. In these cases, optimal esthetic results require proper implant selection and placement, which can be further enhanced by mastopexy.

The sentinel publication by Spear³ in 2003 highlighted the common and possibly severe complications that can occur when augmentation and mastopexy are performed simultaneously. Since that report, several recent articles have reviewed the safety and efficacy of combining these procedures.^{4–6} Although these studies have been useful, the cited complication and revision rates remain substantial.^{7,8} In addition, these publications have been difficult to

interpret because they include a variety of mastopexy techniques, different implant styles, and different implant placements.⁹ This single-surgeon retrospective review quantifies surgical outcomes of a single mastopexy procedure, using the same style saline-filled mammary prostheses in a retropectoral position.

PATIENTS AND METHODS

Between January 2003 and February 2008, 100 women underwent augmentation mammoplasty with periareolar mastopexy under general anesthesia in an accredited ambulatory surgery center by the senior author. Appropriate medical workup and clearance were obtained when indicated. Follow-up photographs were obtained at 2 and 10 months postoperatively.

Surgical Technique

The vertical breast meridian is marked by draping a flexible measuring tape around the posterior neck, over the midportion of the clavicles bilaterally, and intersecting the nipples. The inframammary fold is projected onto this line by pinching the breast tissue. This point represents the desired location of the superior aspect of the areola (Fig. 1). Superior crescents are combined with inferior periareolar markings to give an eccentric elliptical configuration. The width and height of the ellipse vary with the breast dimensions and the planned vertical and/or horizontal reduction of the skin envelope. The saline prostheses are placed in a submuscular position through

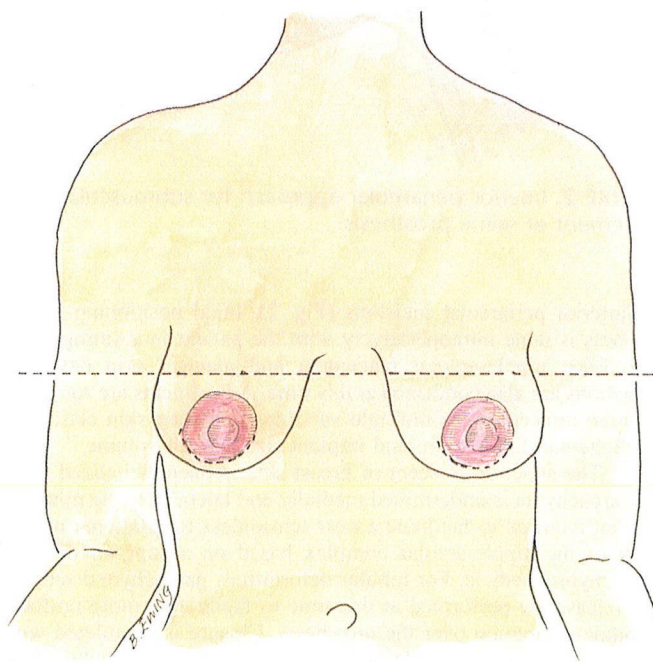


FIGURE 1. The inframammary fold projects the desired location of the superior aspect of the areola.

Received August 9, 2009, and accepted for publication, after revision, February 22, 2010.

From the Department of Plastic and Reconstructive Surgery, Tulane University School of Medicine, New Orleans, LA.

Disclosure: None of the authors has a financial interest to declare in relation to the content of this article.

Presented at the 52nd Annual Meeting of the Southeastern Society of Plastic and Reconstructive Surgeons, Rio Mar, Puerto Rico, June 2009.

Reprints: Clifton L. Cannon III, MD, 2512 Magazine Street, Apartment H, New Orleans, LA 70130. E-mail: CliftonCannonMD@yahoo.com.

Copyright © 2010 by Lippincott Williams & Wilkins

ISSN: 0148-7043/10/6405-0516

DOI: 10.1097/SAP.0b013e3181da438b

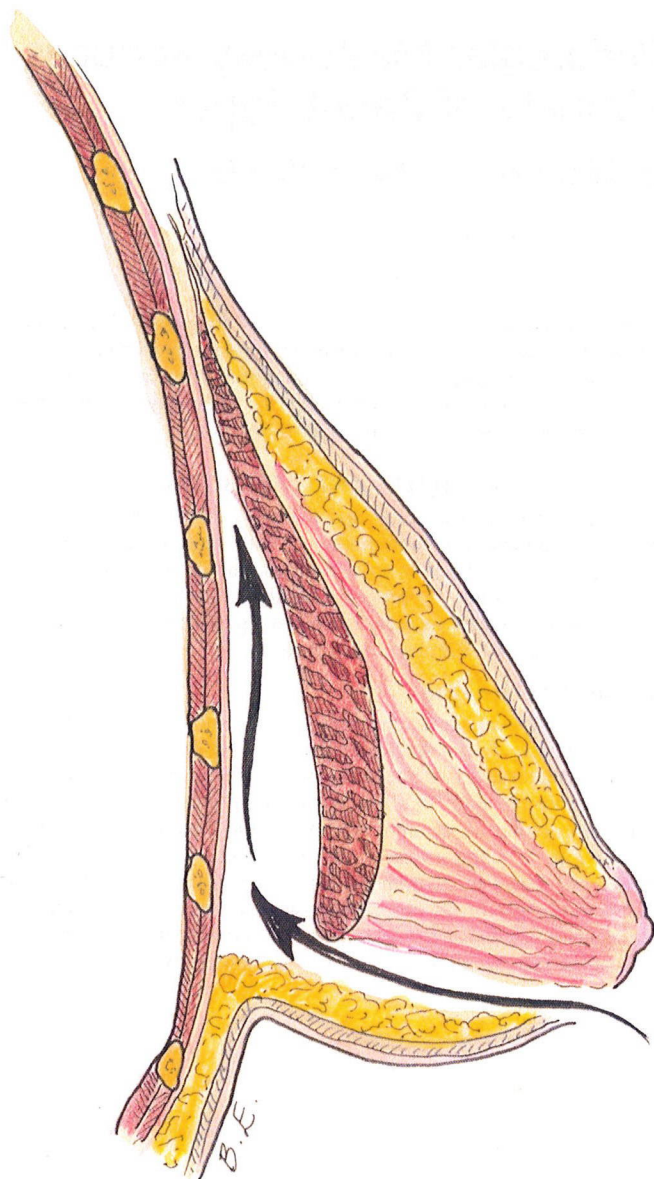


FIGURE 2. Inferior periareolar approach for submuscular placement of saline prosthesis.

the inferior periareolar incisions (Fig. 2). Final positioning of the implants is done intraoperatively with the patient in a sitting position. Final nipple-areolar placement and planned skin envelope reductions are also confirmed at this time. Adjustments are routinely required to account for multiple variables including skin elasticity, parenchymal distribution, and implant size and fill volume.

The superior crescent of breast skin is deepithelialized (Fig. 3). Parenchyma is undermined medially and laterally to the minimal amount required to facilitate a near tensionless translational movement of the nipple-areolar complex based on a superior dermal/parenchymal pedicle. For tubular deformities, parenchymal scoring and release are performed at this time to facilitate a more uniform glandular redraping over the prosthesis. Closure is completed with buried, interrupted, deep dermal 3-0 Vicryl, and subcuticular purse string with 4-0 Vicryl (Ethicon, a Johnson & Johnson company, Somerville, NJ) (Fig. 4).

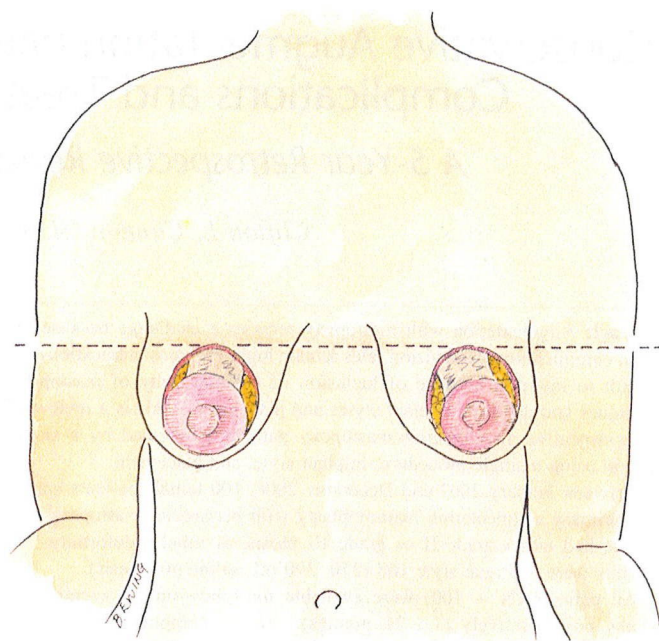


FIGURE 3. Deepithelialized superior crescent gives an eccentric elliptical shape.

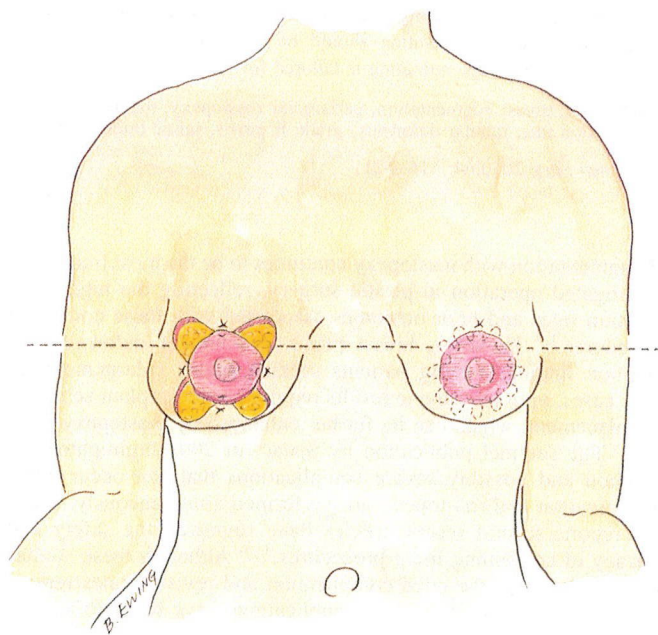


FIGURE 4. Periareolar closure with a subcuticular purse string.

RESULTS

All 100 patients were available for follow-up ranging from 1.5 to 21 months (average 8.3 months) postoperatively. Seventy-six patients had grade 2 breast ptosis, 16 patients had grade 3 breast ptosis, and 8 patients had tubular breast deformity. All implants were Allegan style 168 round, textured (average 330 mL, range 270–390 mL).

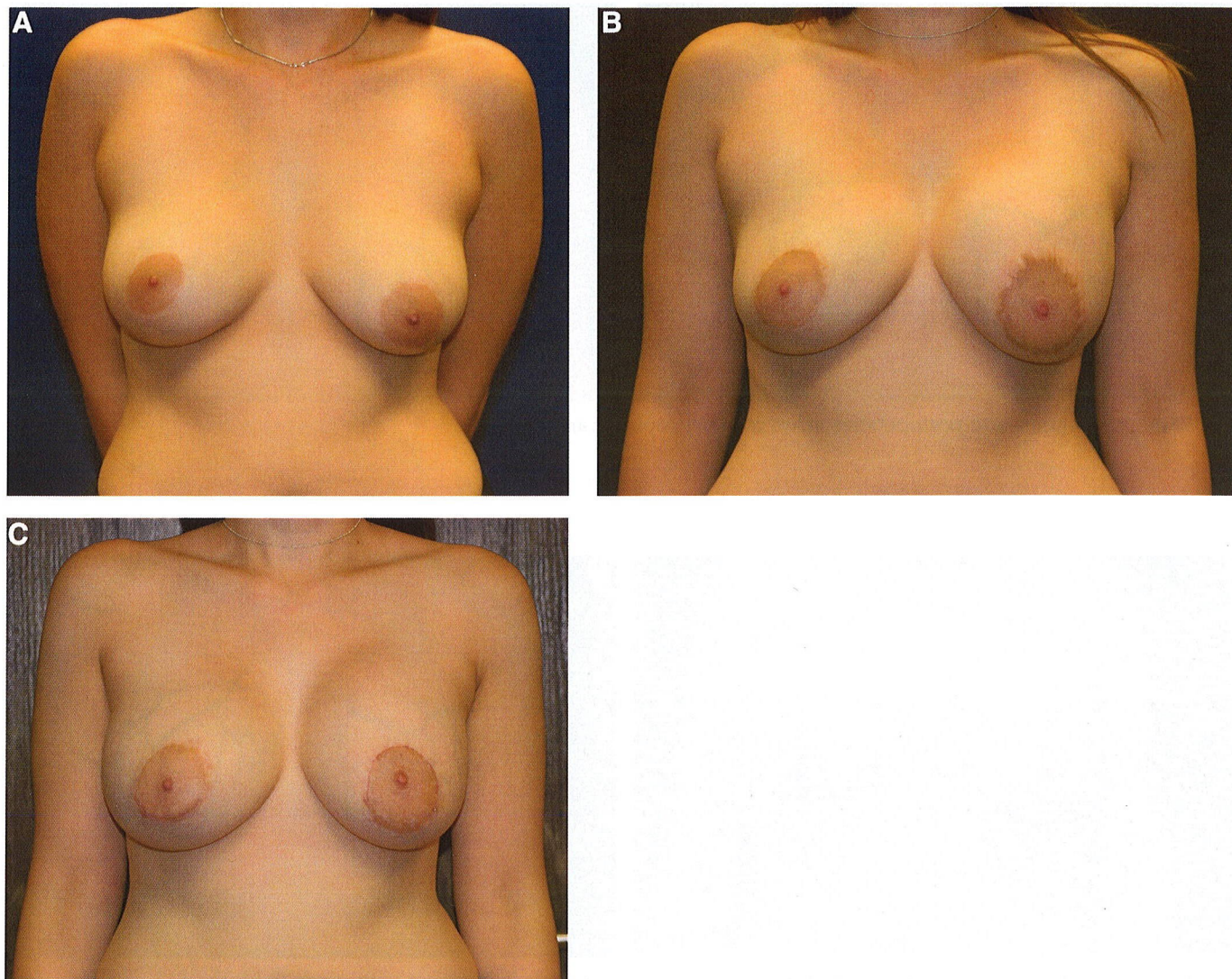


FIGURE 5. Stretched left areola with scar widening (A) preoperatively, (B) postoperatively, (C) after revision.

The overall complication rate in this series was 11%. The nonimplant-related complication rate was 6%. There were 2 (2%) patients who underwent revision under local anesthesia related to areolar stretching and scar widening (Fig. 5). Both of these patients had 330 mL saline implants, and planned nipple-areolar elevation was less than 4 cm. There were 3 cases (3%) of moderate hypertrophic scarring that responded to a single office injection of Kenalog. There were 6 (6%) cases of mild hypertrophic scarring, not considered complications (Fig. 6), that responded to topical Cordran (DPT Laboratories, Ltd., San Antonio, TX) tape. Of the 9 patients experiencing some degree of hypertrophic scarring, 5 had planned nipple elevation of 5 cm or more and 2 had 390 mL implants.

There was 1 (1%) case of partial nipple necrosis that healed secondarily in a patient with grade 3 breast ptosis (Fig. 7). In this patient, the planned nipple-areolar elevation was 7 cm, and the implant size was 390 mL. A summary of nonimplant-related complications is given in Table 1.

The implant-related complication rate was 5%. One (1%) patient presented with infection requiring implant removal and subsequent staged replacement. Two patients (2%) experienced implant deflation requiring replacement. One patient developed a

unilateral mild (Baker grade II) capsular contracture not requiring treatment. One patient experienced mild implant shifting not requiring revision. A summary of implant-related complications is given in Table 2.

When compared with preoperatively, average sternal notch to nipple distance decreased 2.2 cm (0–3.2 cm). Average bust measurement increased to 2.3 inches (0.9–3.4 inches). Representative photographs for patients with grade II ptosis, grade III ptosis, and tubular deformity are shown (Figs. 8–10). There was no observed instance of the “tomato effect” in this series. Pleating in the circum-areolar areas subsided by 6 months postoperatively.

DISCUSSION

We report a low (6%) nonimplant-related complication rate in this series of 100 patients undergoing augmentation with periareolar mastopexy. The complications that did occur were of low severity and correctable except for the 1 patient who experienced partial nipple necrosis. This compares favorably with other series and also allows meaningful analysis of a uniformly applied surgical procedure for a variety of breast types.^{10–12} Although statistical signifi-

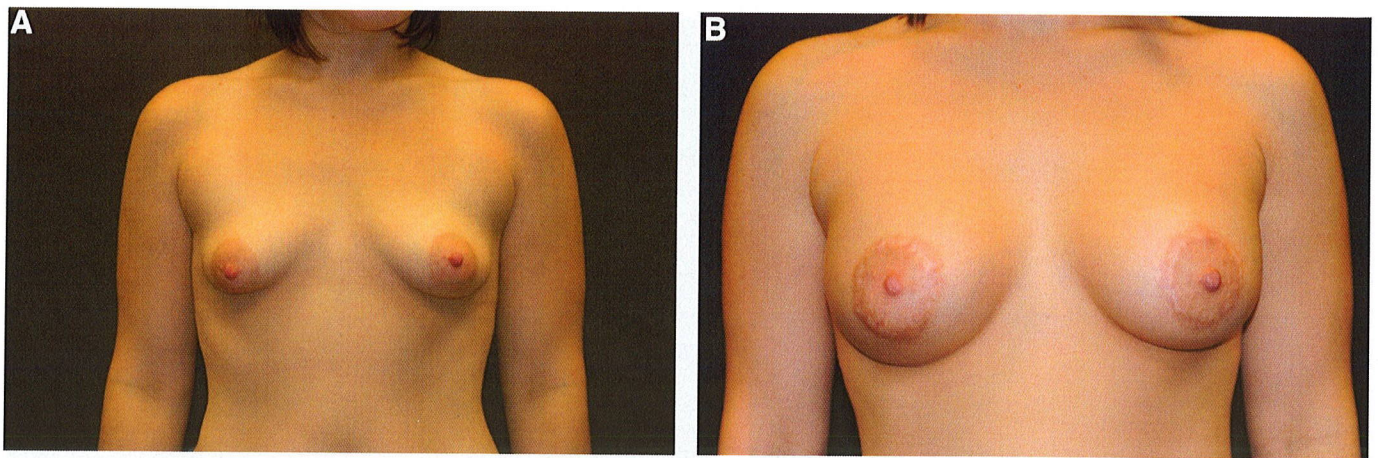


FIGURE 6. Preoperative and postoperative views of hypertrophic scarring.

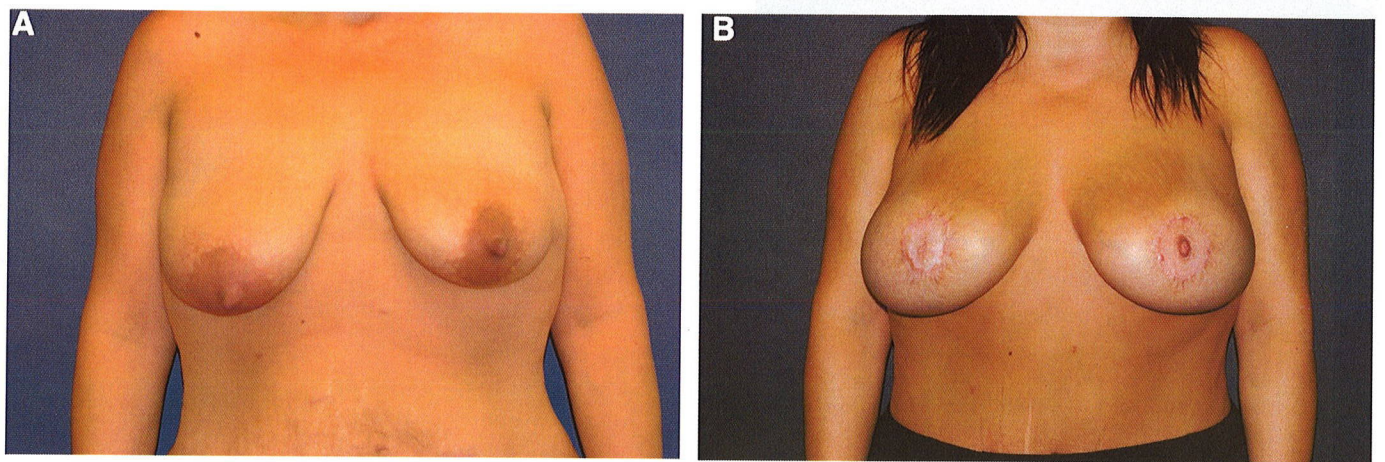


FIGURE 7. Preoperative and postoperative views of partial nipple necrosis in a patient with grade III ptosis.

TABLE 1. Nonimplant-Related Complications

Patients	Complications	Treatment	Comments
2 (2%)	Areolar stretching/scar widening	Revision	Office revision with local anesthesia. Problems resolved.
3 (3%)	Hypertrophic scarring	Intralesional injection with Kenalog	No further treatments required
1 (1%)	Partial nipple necrosis	Conservative wound care, secondary healing	Permanent depigmentation of the inferior areolar skin and loss of nipple projection

TABLE 2. Implant-Related Complications

Patients	Complications	Treatment	Comments
1 (1%)	Unilateral infection	Explantation	Successful reimplantation after 6 months
1 (1%)	Mild implant shifting	None	No revision requested or recommended
1 (1%)	Unilateral Baker II capsular contraction	None	No revision requested or recommended
2 (2%)	Implant deflation	Replacement	Cosmetic outcome not affected

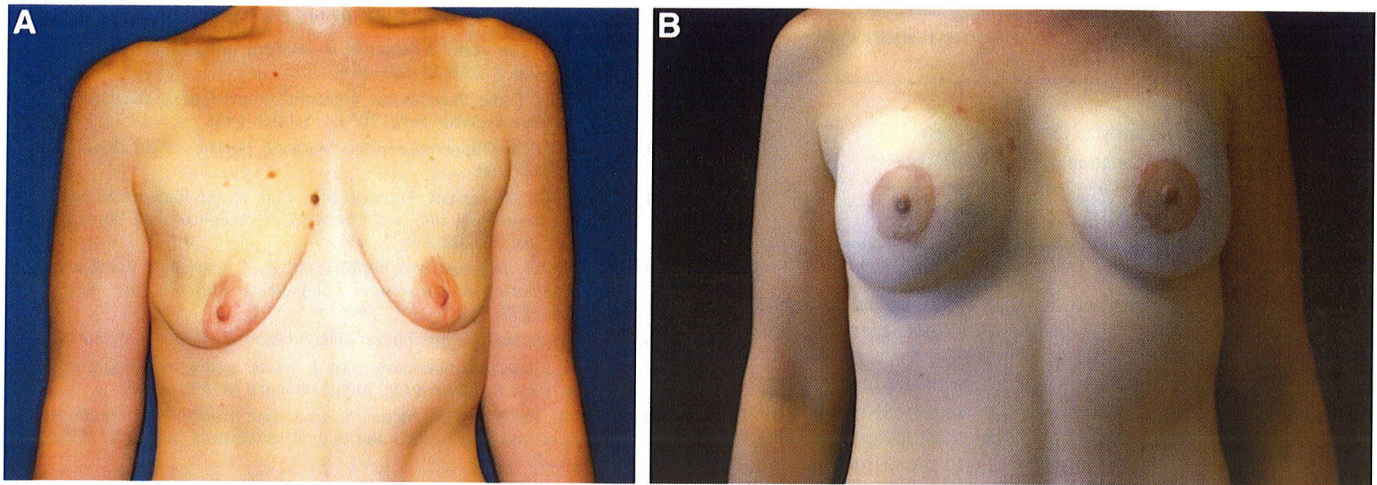


FIGURE 8. Preoperative and postoperative views of grade II ptosis after augmentation and periareolar mastopexy.

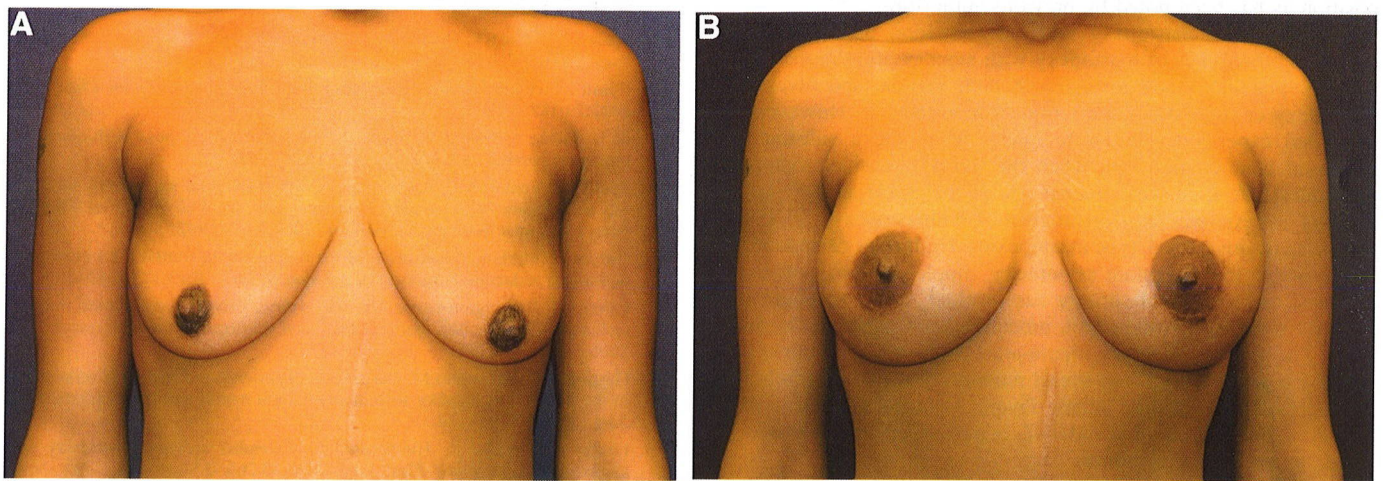


FIGURE 9. Preoperative and postoperative views of grade III ptosis after augmentation and periareolar mastopexy.

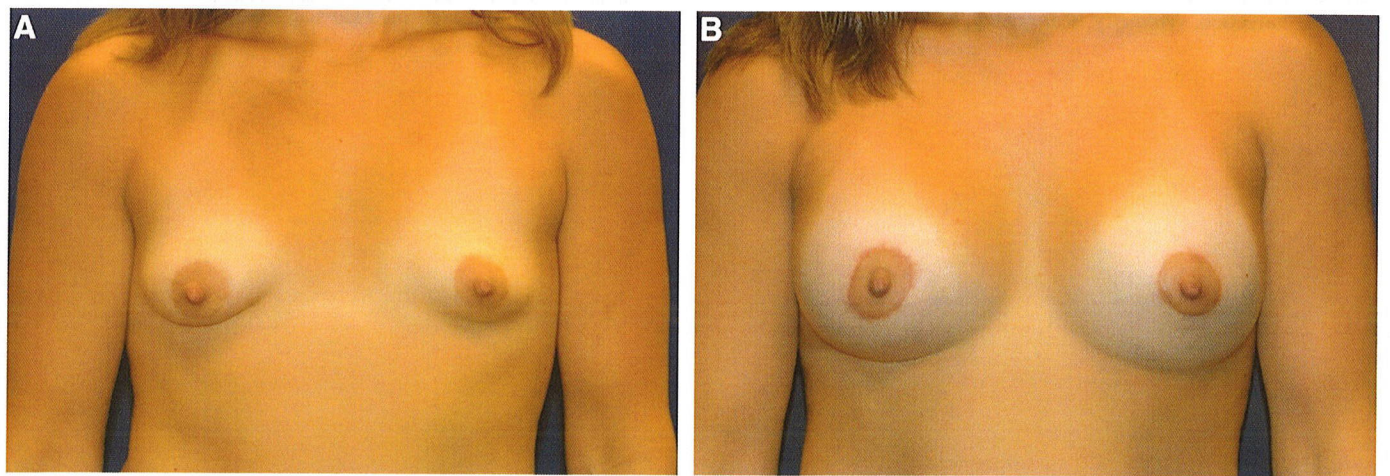


FIGURE 10. Preoperative and postoperative views of tubular breast deformity after augmentation and periareolar mastopexy.

TABLE 3. Favorable Factors for Augmentation With Periareolar Mastopexy

1. Flaccid, empty breasts
2. Small to moderate implant size (360 mL or less)
3. Planned nipple-areolar elevation 4 cm or less
4. Lighter skin tones
5. Absence of deep stretch marks

cance could not be achieved in this small series, conservative augmentation with periareolar mastopexy reduces complications and increases predictability. Factors that mitigate for a favorable result are summarized in Table 3 and have been cited previously.^{13–15}

A major difference between this and previous publications lies in the preoperative planning. Most mastopexy and reduction procedures rely on the anterior projection of the inframammary fold onto the breast meridian to define desired nipple position.^{14,16} With the combined augmentation/periareolar mastopexy, this landmark represents the desired location of the superior aspect of the areola. However, this recommendation is an approximation, and the final position is determined intraoperatively with the patient in the sitting position as has been noted by previous authorities.^{17–19}

Periareolar mastopexy with augmentation has now superseded all other types of mastopexy with augmentation in the senior author's practice. Good results with both vertical and inverted-T mastopexy configurations are routinely reported.^{20,21} However, we have had experience similar to others who note a substantially increased complication rate when the more extensive mastopexy procedures are used. In a recent review by Spear et al,²² of 34 patients undergoing revision augmentation/mastopexy, 20 (59%) had previous inverted-T type mastopexies. High rates of widened or unacceptable scars, implant asymmetry, nipple necrosis, soft tissue necrosis, and revisional surgery has resulted in our recommendations for a more narrow patient, procedure, and implant selection.

For patients requiring nipple-areolar elevation greater than 4 cm or for patients requiring breast mound repositioning (including pseudoptosis), the senior author favors a staged approach. Mastopexy, either vertical or inverted-T, is performed first followed by staged augmentation 6 months later.

Although we report our success combining these procedures, we note that these are short-term results needing long-term observation. Implant-related complications such as deflation, contracture, displacement, and wrinkling will steadily increase with time. However, we believe the follow-up provided in this study does allow for assessment of ptosis correction, symmetry, scar quality, and patient satisfaction.

REFERENCES

1. Gorney M. Ten years' experience in aesthetic surgery malpractice claims. *Aesthetic Surg J.* 2001;21:569–571.
2. Hoffman S. Some thoughts on augmentation/mastopexy and medical malpractice. *Plast Reconstr Surg.* 2004;113:1892–1893.
3. Spear S. Augmentation/mastopexy: "surgeon, beware". *Plast Reconstr Surg.* 2003;112:905–906.
4. Stevens WG, Stoker DA, Freeman ME, et al. Is one-stage breast augmentation with mastopexy safe and effective? A review of 186 primary cases. *Aesthetic Surg J.* 2006;26:674–681.
5. Stevens WG, Freeman ME, Stoker DA, et al. One-stage mastopexy with breast augmentation: a review of 321 patients. *Plast Reconstr Surg.* 2007;120:1674–1679.
6. Becker H. Subareolar mastopexy: update. *Aesthetic Surg J.* 2003;23:357–363.
7. Spear SL. Augmentation/mastopexy: a 3-year review of a single surgeon's practice. *Plast Reconstr Surg.* 2006;118(suppl 7):136S–147S.
8. Spear SL, Pelletiere CV, Menon N. One-stage augmentation combined with mastopexy: aesthetic results and patient satisfaction. *Aesthetic Plast Surg.* 2004;28:259–267.
9. Don Parsa F, Brickman M, Parsa AA. Augmentation/mastopexy. *Plast Reconstr Surg.* 2005;115:1428–1429.
10. Ribeiro L, Accorsi A Jr, Argencio V. Tuberos breasts: a periareolar approach. *Aesthetic Surg J.* 2005;25:398–402.
11. Rohrich RJ, Thornton JF, Jakubietz RG, et al. The limited scar mastopexy: current concepts and approaches to correct breast ptosis. *Plast Reconstr Surg.* 2004;114:1622–1630.
12. Spear SL, Giese SY, Ducic I. Concentric mastopexy revisited. *Plast Reconstr Surg.* 2001;107:1294–1299.
13. Elliott LF. Circumareolar mastopexy with augmentation. *Clin Plast Surg.* 2002;29:337–347.
14. de la Fuente A, Martin del Yerro JL. Periareolar mastopexy with mammary implants. *Aesthetic Plast Surg.* 1992;16:337–341.
15. Spear SL, Venturi ML. Augmentation with periareolar mastopexy. In: Spear SL, ed. *Surgery of the Breast: Principles and Art.* Vol. 2, 2nd ed. Philadelphia: Lippincott Williams & Wilkins; 2006:1393–1402.
16. Gulyas G. Marking the position of the nipple-areola complex for mastopexy and breast reduction surgery. *Plast Reconstr Surg.* 2003;113:2085–2090.
17. Fahmy S, Hemington-Gorse SJ. The sitting, oblique, and supine marking technique for reduction mammoplasty and mastopexy. *Plast Reconstr Surg.* 2006;117:2145–2151.
18. Gasperoni C, Salgarello M, Gargani G. Experience and technical refinements in the "donut" mastopexy with augmentation mammoplasty. *Aesthetic Plast Surg.* 1988;12:111–114.
19. Gruber R, Denkler K, Hvistendahl Y. Extended crescent mastopexy with augmentation. *Aesthetic Plast Surg.* 2006;30:269–274.
20. Lassus C. A 30-year experience with vertical mammoplasty. *Plast Reconstr Surg.* 1996;97:373–380.
21. Hidalgo DA. Improving safety and aesthetic results in inverted T scar breast reduction. *Plast Reconstr Surg.* 1999;103:874–886.
22. Spear SL, Low M, Ducic I. Revision augmentation mastopexy: indications, operations, and outcomes. *Ann Plast Surg.* 2003;51:540–546.